

## FACIAL ATTRACTIVENESS AND ASYMMETRY- A REVIEW ON COMPREHENSIVE DIAGNOSIS AND MANAGEMENT

Pravinkumar S Marure, \* Siddarth Arya, \*\* Kiran H, \*\*\* Dharmesh H S †

\* Senior Lecturer, Department of Orthodontics, MIDSR Dental College & Hospital, Latur, Maharashtra, India

\*\* Senior Lecturer, Department of Orthodontics & Dentofacial Orthopedics, Rajarajeshwari Dental College & Hospital, Bengaluru, Karnataka, India

\*\*\* Reader, Department of Orthodontics & Dentofacial Orthopedics, Rajarajeshwari Dental College & Hospital, Bengaluru, Karnataka, India

† Senior Lecturer, Department of Orthodontics & Dentofacial Orthopedics, Rajarajeshwari Dental College & Hospital, Bengaluru, Karnataka, India

### ABSTRACT

Facial esthetics is an important personal and social concern. Attractive facial appearances are judged to possess more socially desirable personality traits and favourable facial esthetics is related to psychosocial well-being by children, young adults, and parents. In addition, parents believe their child would become better liked, more successful, and overall more attractive because of esthetic. As the demand for improved facial esthetics increases, more patients complain of the development or the progression of facial asymmetry, particularly mandibular asymmetry, during. Patients who undergo orthognathic surgery for sagittal relationship problems, such as maxillary protrusion or mandibular prognathism, also tend to become aware of facial asymmetry after the surgical procedure. Because a misdiagnosis of facial asymmetry can result in the wrong treatment for a patient, accurate evaluations of facial asymmetry are crucial in orthodontic practice. Hence, diagnosis and management of facial asymmetry is an important concern within the specialty of orthodontics.

**KEYWORDS:** Facial asymmetry; Esthetics; Mandibular asymmetry; Condylar asymmetry

### INTRODUCTION

Symmetry, when applied to facial morphology, refers to the correspondence in size, shape, and location of facial landmarks on the opposite sides of the median sagittal plane.<sup>[1]</sup> Perfect bilateral body symmetry is largely a theoretical concept that seldom exists in living organisms. Right-left

differences occur everywhere in nature where two congruent but mirror image types are present. Some of these asymmetries are embryonically rooted and are associated with asymmetry in the central nervous system.<sup>[2]</sup> Facial symmetry has a high correlation with attractiveness. Greater degrees of asymmetry are correlated with clinical depression, neurosis, inferiority complex, poor self-esteem, and general poor-quality-of-life health problems.<sup>[3]</sup>

### Facial Esthetics, Beauty and Attractiveness

*Esthetics*, derived from the Greek word *aisthetikos*.<sup>[4]</sup> Ancient Egyptians were possibly the first to describe ideal facial and bodily proportions in grid or mathematical form. Sculptures made during this period conformed to established proportions of beauty, as in the so called *Bartlett Head of Aphrodite* sculpture (Fig. 1).<sup>[5]</sup> A ancient greatest statues that display proportional ideals of beauty include the Statue of Zeus at Olympia and Athena Parthenos (Fig. 2). Cephalometric guidelines for facial esthetics were first introduced after the development and standardization of the roentgenographic cephalometer by B. Holly Broadbent, Sr., in 1931.<sup>[6,7]</sup>

### Esthetic Ideals in Orthodontics

Esthetic ideals used in orthodontic diagnosis and treatment planning have evolved from artistic, anthropometric and cephalometric guidelines. To make an objective differentiation between minor and major asymmetry, it is advisable to quantify asymmetry. Quantification makes it possible to demonstrate the amount of asymmetry for diagnostic purposes. Qualitative on the other hand allows diffentiation between problems of skeletal, dental or soft tissue origin thus suggesting the diagnosis, treatment planning and designing of




**Fig. 1:** The so-called Bartlett



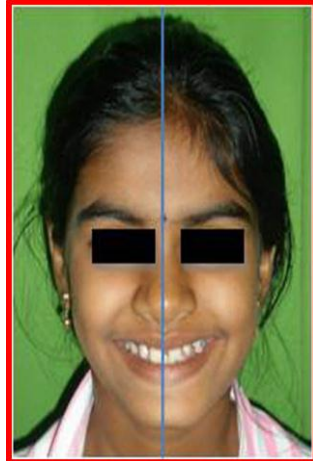
**Fig. 2:** A replica of Phidias's



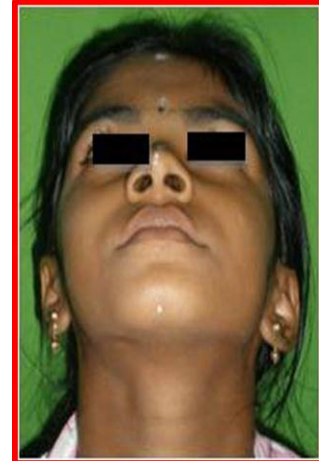**Fig. 3:** Severe hemifacial



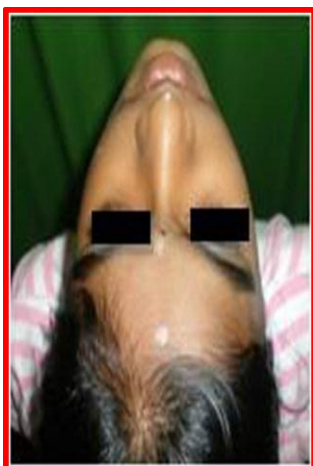**Fig. 4a:** Front face



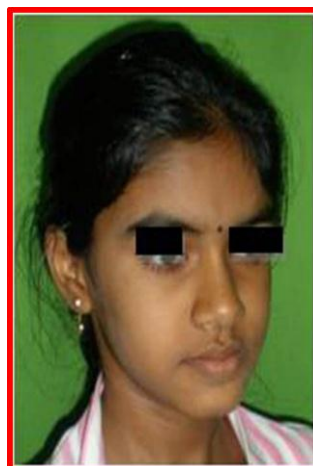**Fig. 4b:** Front face smiling



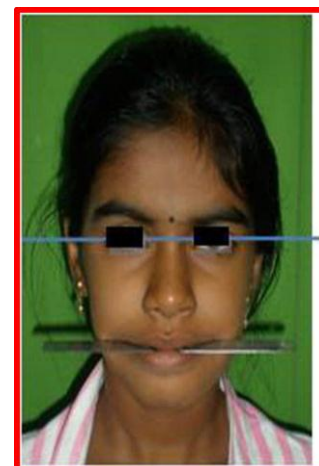
**Fig. 4c:** Submental view



**Fig. 4d:** Superior view



**Fig. 4e:** Three quarter face views



**Fig. 5:** Vertical occlusal evaluation

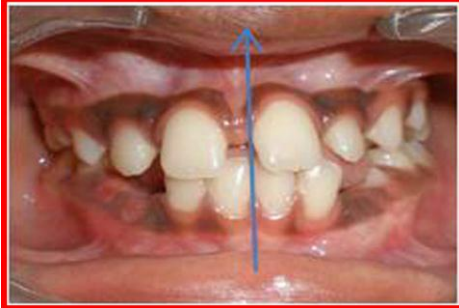mechanics.<sup>[8,9]</sup>

**EPIDEMIOLOGY OF ASYMMETRIES**

In all investigations a significant facial asymmetry has been demonstrated even in aesthetically pleasing faces, but no agreement exists about the side of dominance. Although Vig & Hewitt,<sup>[10]</sup> found in their radiographic

investigation that the cranial base and maxillary regions were significantly larger on the left side, Shah & Joshi,<sup>[11]</sup> stated that the total facial structure was larger on the right side. Woo,<sup>[12]</sup> working on skulls, found that the right frontal and parietal bones were larger than the left, but that the left malar bone was predominant. In the

photographic study by Ferarrio *et al.*<sup>[13]</sup> the lower part of the face was dominant on the right side in both men and women and Melnik,<sup>[14]</sup> showed that the side of facial dominance.



**Fig. 6:** Evaluation of dental midlines

### ETIOLOGY

- 1) **Skeletal Asymmetries:** There are multiple causes of facial asymmetry, but the differential can be separated into three classes: congenital, developmental, and acquired. *Congenital* anomalies are conditions acquired during in utero development.<sup>[15,16]</sup> *Developmental* anomalies are conditions arising during post-uterine growth through adulthood such as: Hemimandibular Hyperplasia/Elongation. *Acquired* anomalies are conditions arising from either trauma or pathology, e.g. Condylar Trauma; Hemifacial microsomia (Fig. 3).<sup>[17,18]</sup>
- 2) **Dental Asymmetries:** Lundstrom, in a detailed study of the asymmetries in the dental arches and faces, explained that asymmetry can be genetic or non-genetic in origin, and usually a combination of both. Causes for dental asymmetries are, Ankylosis of Primary Molars; Premature Deciduous Tooth Exfoliation; Congenitally Missing Teeth; Space Loss Due To Interproximal Caries; Ectopic Eruption of Mandibular Lateral Incisors; Habits etc.<sup>[17,19]</sup>

### CLASSIFICATION OF ASYMMETRIES

According to Lundstrom, asymmetries can be classified as:<sup>[2,17,20,21]</sup>

- 1) **Dental asymmetries:** Dental asymmetry can also be further classified as: Vertical (e.g. Canted occlusion), Transverse (e.g. Posterior cross bite) and Anteroposterior (e.g. anterior crossbite).
- 2) **Skeletal asymmetries:** The deviation may involve one bone such as the maxilla or mandible or it may involve a number of

skeletal and muscular structures on one side of the face, e.g. Hemifacial microsomia

- 3) **Muscular asymmetries:** Facial disproportions and midline discrepancies could be the result of muscular asymmetry.
- 4) **Functional asymmetries:** These can result from the mandible being deflected laterally or antero-posteriorly, if occlusal interferences prevent proper intercuspation in centric relation.

### DIAGNOSIS OF FACIAL AND DENTAL ASYMMETRIES

A thorough clinical examination and radiographic examination are necessary to determine the extent of the soft tissue, Skeletal, Dental and Functional involvement.<sup>[2,22,23]</sup>

- 1) **Clinical Examination:** Patient should be seated upright with good posture orbit, globe, nose and zygoma are evaluated for form and symmetry Auricles are inspected for symmetry in form, projection and placement.
- 2) **Medical History:** The patient population seeking treatment for correction of dentofacial deformities are widely varied in age and generally has no serious coexisting medical conditions, however particular attention must be given to cardiopulmonary endocrine, hematologic, neurologic and allergic problems in the medical history.
- 3) **Dental Evaluation:** It includes the history of previous orthodontic, surgical, restorative, periodontal and prosthodontic treatment.
- 4) **Social-psychologic Evaluation:** The psychologic makeup of the patient is important because, despite an objectively favorable treatment result, certain patient will express dissatisfaction with their results.
- 5) **Photograph for Facial Evaluation:** The photographic views are essential in diagnosing facial and dental asymmetries.

**Front face** (Fig. 4a): The evaluation of facial asymmetries is initially carried out by constructing on a front face photograph a line that represents the patient's true facial midline.

**Front face smiling** (Fig 4b): It permits assessment and documentation of the relation of the dental midlines to the facial midline and the clinical relevance of any occlusal plane cant. This photo should be taken with patient's interpupillary and Frankfort horizontal plane parallel to the floor.

**Submental view** (Fig. 4c): The submental view is taken with the patient's head hyper extended about 45 degrees. It is useful to assess symmetry and projection of the anterior cranial vault, orbital areas and cheeks. Nasal deformities are also well documented and studied in this view

**Superior view** (Fig. 4d): The superior view is taken with the patient's head hyperflexed about 45 degrees. Like the submental view, it is useful in assessing anterior cranial vault, orbital cheek and nasal deformities. It is often more useful than the submental view for demonstrating and diagnosing cheek deformities.

**Three quarter face views** (Fig. 4e): Three quarter face views are taken with the patient's head turned midway (45 degrees) between the front face and profile view. The primary use of this view is to document and diagnose facial anomalies associated with the auricular and preauricular areas, the mandibular angle, and the ascending ramus of the mandible, the nose, and the cheeks.

6) **Masticatory muscle evaluation:** The masticatory muscle examination has two primary functions. First, to identify any painful and / or trigger points. Second, to identify the deficient masticatory muscle mass that often exists in patients who have sustained trauma to this area or who have undergone previous orthognathic surgery.

7) **TMJ examination:** TMJ is palpated, auscultated and examined for any pain, clicking sounds and for normal position and movements of condyle.

8) **Intra-oral examination:**

**Vertical occlusal evaluation:** The presence of a canted in the occlusal plane could be the result of a unilateral increase in the vertical length of the condylar and ramus (Fig. 5).

**Evaluation of dental midlines:** The clinical examination should include an evaluation of the dental midlines in the following positions: mouth open; in centric relation; at initial contact and in centric occlusion (Fig. 6).

**Transverse and antero-posterior occlusal evaluations:** Asymmetry in the bucco-lingual relationship, e.g. a unilateral posterior crossbite, should be carefully diagnosed to determine if it is dental, skeletal or functional. Asymmetrical arch shape in transverse and AP

direction can be assessed using a Symmetrograph (Fig. 7).

9) **Radiographical Evaluation:** In addition to the clinical evaluation, differentiation between various types of asymmetries can be aided by the use of radiographs.

**Lateral Cephalometric Radiographs:** A lateral cephalometric radiograph can provide clues of vertical differences by the lack of superimposition (e.g. two separate radiographic mandibular inferior borders). However, to determine the relative significance of the differences in dentofacial superimposition, one must know whether the external auditory canals are level with the patient's natural head position.<sup>[22]</sup>


**Panoramic Radiographs:** The panoramic radiograph can provide information regarding the relative height of the mandibular condyle and ramus. To find presence of gross pathology, missing or supernumerary teeth can be determined.<sup>[24]</sup>

**Postero-anterior projection (PA ceph):** The posteroanterior cephalometric radiograph enables one to understand the extent of the deformity relative to the cranial base. The PA cephalometric analysis such as: Rocky mountain analysis- Ricketts, Hewitt, Svanholt & Solo, Chierici, Multi planar cephalometric Analysis - Grayson and Bookstein, Grummons & Kappeyene analysis and Proffit.

10) **Recent Advances in Diagnostic imaging for Asymmetry:** Today we are experiencing an explosion in CT technology. Innovative scanners, advanced applications and exciting breakthroughs in clinical procedures. The objective quantification of facial asymmetries can be performed with the use of 3D technologies such as; CT scans, CBCT, Laser scanning, OrthoCAD and E-Models, 3D occlusograms, MRI for soft tissue asymmetry, Skeletal Scintigraphy, Stereolithographic Modeling, Technetium 99m Phosphate, Bone Scans etc.<sup>[25]</sup>

## MANAGEMENT

A detailed study of the various diagnostic records obtained on the patient is necessary in order to determine the cause, location, and extent of the asymmetry. This will enable the clinician to formulate the proper treatment plan.<sup>[2,26,27]</sup>



**Fig. 7:** Symmetrogram

**Management of dental asymmetry:** True dental asymmetries, such as with a congenitally missing lateral incisors or second premolars, are often treated orthodontically. Asymmetric extraction sequences and asymmetric mechanics, e.g. class III elastics on one side and class II elastics on the other with oblique elastic anteriorly, can also be used to correct dental arch asymmetries.

**Management of Functional asymmetries:** Mild deviations due to functional shifts are sometimes corrected with minor occlusal adjustments. More severe deviations need orthodontic treatment to align the teeth and to obtain proper function. Occlusal splints used to eliminate habitual posturing and deprogramming the musculature. Since functional shifts can also be the result of a skeletal asymmetry, rapid maxillary expansion, orthognathic surgery and orthodontic treatment may be indicated in the management of these cases.



**Fig. 8:** Leonardo Da Vinci creation "MONA LISA"

**Management of skeletal asymmetries:** The severity and nature of the skeletal asymmetry will dictate whether the discrepancy can be completely or partially resolved solely through orthodontic treatment. In growing individuals, orthopaedic appliances in conjunction with

orthodontic treatment are used to help improve or correct developing skeletal imbalances. Severe discrepancies may require a combination of surgery and orthodontic treatment.

**Management of soft tissue asymmetries:** Deformities due to soft tissue imbalance can be treated by either augmentation or reduction surgery. Augmentations include the use of bone graft and implants to recontour the desired areas of the face.

### CONCLUSION

Patients presenting with significant clinical asymmetry pose special diagnostic and treatment challenges to the orthodontist. Determination of underlying cause of the asymmetry, meticulous clinical and radiographic evaluation and related dental cast analysis in centric relation and occlusion, as well as thorough review of the past medical and dental history, is necessary to evaluate the asymmetry in 3 planes of space. Asymmetries may be skeletal/ dental or functional in origin or combination of the above. It is essential to determine if the asymmetry is stable or progressive in nature, secondary to abnormal growth or pathology, before formulating a treatment plan. The most accepted symmetrical face in the universe Leonardo Da Vinci creation "MONA LISA" As an orthodontist all of us aim for that (Fig. 8).

### BIBLIOGRAPHY

1. Peck BS, Peck L, Kataja M. Skeletal asymmetry in esthetically pleasing faces. *Angle Orthod.* 1991;61:43-48.
2. Bishara SE, Burkey PS, Kharouf JG. Dental and facial asymmetries: A review. *Angle Orthod.* 1994;64(2):89-98.
3. Shackelford TK, Larsen RJ. Facial asymmetry as an indicator of psychological, emotional, Physiological distress. *J Pers Soc Psychol.* 1997;72:456-66.
4. Baumgarten AG. *Aesthetica.* Paris: L'herne; 1989.
5. Edler RJ. Background considerations to facial aesthetics. *J Orthod.* 2001;28:159-68.
6. Ricketts RM. The biological significance of the divine proportion and Fibonacci series. *Am J Orthod.* 1982;81:351-70.
7. Angle EH. *Treatment of malocclusion of the teeth and fractures of the maxillae,* Angle's system, 6th ed. Philadelphia: SS White Dental Mfg Company 1900.

8. Case CS. A practical treatise on the techniques and principles of dental orthopedia and correction of cleft palate, 2nd ed. Chicago: CS Case and Company 1922.
9. Angle EH. Malocclusion of the teeth, 7th ed. Philadelphia: SS White Dental Mfg Company 1907.
10. Vig PS, Hewitt AB. Asymmetry of the human facial skeleton. *Angle Orthod.* 1975;45:125-129.
11. Shah SM, Joshi MR. An assessment of asymmetry in the normal craniofacial complex. *Angle Orthod.* 1978;48:141-148.
12. Woo TL. On the asymmetry of the human skull. *Biometrika.* 1931;22:324-352.
13. Ferrario VF, Sforza C, Pizzrni G, Vogel G, Miani A. Sexual dimorphism in the human face assessed by Euclidean distance matrix analysis. *Journal of Anatomy.* 1993;183:593-600.
14. Melnik AK. A cephalometric study of mandibular asymmetry in a longitudinally followed sample of growing children. *Am J Orthod Dentofacial Orthop.* 1992;101:355-366.
15. Cohen MM Jr. The child with multiple birth defects. New York: Raven Press; 1982.
16. Cohen MM. Perspectives on craniofacial asymmetry. The biology of asymmetry. *Int J Oral Maxillofac Surg.* 1995;24:2-7.
17. Lundstrom A. Some asymmetries of the dental arches, and skull, and their etiological significance. *Am J Orthod.* 1966; 47:81-106.
18. Boder E. A common form of facial asymmetry in the newborn infants: its etiology and orthodontic significance. *Am J Orthod.* 1953;39:895.
19. Vagervik K. Orthodontic management of unilateral cleft lip and palate. *Cleft Palate J.* 1981;18:256.
20. Bart RS, Kopf AW. Hemifacial atrophy. *J dermatol surg oncol Tumour conference* #20: 1978;4:908.
21. Person M. Mandibular asymmetry of hereditary origin. *Am J Orthod.* 1973;63:1-11.
22. Hegtvedt AK. Diagnosis and management of facial asymmetry. In: Principles of oral and maxillofacial surgery. Philadelphia: JB Lippincott Company. 1992;1400-14.
23. Cheney EA. Dentofacial asymmetries and their clinical significance. *Am J Orthod.* 1961;47:814-829.
24. Lewis PD. The deviated midline. *Am J Orthod.* 1976;70:601-616.
25. Hyeon-Shik H, Hyon HC, Ki-Heon L, Byung-Cheol K. Maxillofacial 3-dimensional image analysis for the diagnosis of facial asymmetry. *Am J Orthod Dentofacial Orthop.* 2006;130:779-85
26. Sarnas KV, Pancherz H, Rune B Selvik G. Hemifacial microsomia treated with the Herbst appliance. *Am J Orthod.* 1982;82:68-74.
27. Gorney M, Harries T. The preoperative and post-operative consideration of natural facial asymmetry. *Plast reconstr surg.* 1974;54:187.

**Source of Support: Nil**  
**Conflict of Interest: Nil**